

A New Algorithm in the Diagnosis of Thyroid Nodules

Hasan Zafer Acar¹ and Nazmi Özer^{2*}

¹*Department of General Surgery, Faculty of Medicine, Girne American University, 99428, Kyrenia, Cyprus.*

²*Department of Biochemistry, Faculty of Pharmacy, Girne American University, 99428, Kyrenia, Cyprus.*

Authors' contributions

This work was carried out in collaboration between both authors. Both authors read and approved the final manuscript.

Article Information

Editor(s):

(1) Dr. Engbang Ndamba Jean Paul, University of Douala, Cameroon.

Reviewers:

(1) Chibao Huang, Zunyi Normal University, China.

(2) Rafal Al-Rawi, Hawler Medical University, Iraq.

Complete Peer review History: <http://www.sdiarticle4.com/review-history/69940>

Original Research Article

Received 06 April 2021

Accepted 12 June 2021

Published 14 June 2021

ABSTRACT

The most important problems in the follow-up of thyroid nodules are missing cancer cases or performing unnecessary thyroidectomy.

The aim of this study is to create a more sensitive, risk free and cost-effective algorithm in the follow-up of thyroid nodules. For this purpose, the current methods used in the diagnosis of thyroid nodules were examined in our study.

As a method to achieve our aim in our study; based on the results of current studies on this subject, noninvasive serum molecular marker diagnosis methods, which have been shown to be superior to invasive biopsy methods in the diagnosis of thyroid cancers in terms of sensitivity, risk and cost, were given priority over invasive biopsy methods in the algorithm and as a result, in this new algorithm; it has been demonstrated that the possibility of missed thyroid cancer cases may be less, and unnecessary surgeries can be prevented at a lower cost.

However, to come to a definitive conclusion about this, our model should be applied in large case series and results should be compared with others.

Keywords: Thyroid nodules; thyroid cancers; algorithm for thyroid nodules.

ABBREVIATIONS

ACE : Association of Clinical Endocrinologists;
ATA : American Thyroid Association;
BTA : British Thyroid Association;
CI : Concordance Index;
EGFR : Endothelial Growth Factor Receptor;
ETA : European Thyroid Association;
2D-SWE : Two-Dimensional Shear Wave Elastography;
FNA : Fine Needle Aspiration biopsy;
DUS : Doppler Ultrasonography;
GEP : Gene Expression Profiling;
GSUS : Gray Scale Ultrasonography;
NLR : Negative Likelihood Ratio;
PPV : Positive Predictive Value;
PTC : Papillary Thyroid Cancer;
PTH : Papillary Thyroid Hyperplasia;
TC : Thyroid Cancer;
TIRADS : Thyroid Imaging Reporting And Data System;
US : Ultrasonography;
USE : US Elastography;
VEGF : Vascular Endothelial Growth Factor.

1. INTRODUCTION

The most important dilemma of thyroid nodules; not to missing cancer cases and not operate the patient unnecessarily. Therefore, the methods used in the diagnosis of thyroid nodules; should be effective (sensitive), not to missing cancer cases (risk free) and cost/benefit ratio should be low (cost-effective).

Although, thyroid nodules are a very common disease, only 5-8% are Thyroid Cancer (TC) [1]. Fine Needle Aspiration biopsy (FNA) is the most commonly used method in the diagnosis of thyroid nodules. It is a sensitive and relatively risk free method. However, there are some disadvantages of FNA. The aim of this study is to create a more sensitive, risk free and cost-effective algorithm in the follow-up of thyroid nodules.

In a study by Pinchot et al. [2], he said that thyroidectomy should be performed directly in the nodules larger than 4 cm since FNA finds the false negative rate more than 50% .

Giles et al. [3] compared the histopathological results of 323 thyroid nodules whose FNA results were benign. False negative diagnosis rate in all nodules; 11.7%, in nodules between and 3-3.9

cm; 12.8%, in nodules larger than 4 cm; 11% , and 4.8% in nodules of 3 cm or less.

In a study conducted by Raad et al. [4] in 738 cases who detected benign cytology in FNA, the result of histopathological examination after the operation was found to be false negative in 5% . Furthermore, the FNA material from 661 thyroid nodules, were the false negative rate increased to 2% in nodules larger than 3 cm [5]. In the same study, when the cytological findings were compared with histopathological findings, the sensitivity rate 96.7%; specificity 85.9%; positive predictive value 76.6%; negative predictive value 98.2%, and accuracy 89.4% [5].

In FNA performed by 4077 nodules in 3767 patients by Choi et al., [6] 16.1% of cases were insufficient cytology and 4.1% undetermined cytological results were obtained. In this study, the most important factor that increased the rate of obtaining insufficient cytological material was not the diameter of the nodule, but the inexperienced physician performing the biopsy [6].

In a meta-analysis performed by Ospina et al. on 32 studies, the accuracy of the diagnosis were analyzed in the Ultrasonography (USG)-guided FNAs [7]. The results obtained are explained practically as follows: 8 out of 10 cases with suspicion of malignancy in the USG emerged. When FNA was performed in 10 cases where USG findings were found benign, this number decreased to 3. Only one in 10 cases with low malignancy suspicion in the USG was detected.

The probability of malignancy was found to be less than 1% in cases where FNA performed with USG was found to be benign. Follicular cancer was found in 71% of patients with suspected follicular neoplasm in FNA.

In multi-centered papillary thyroid cancers, which is about 20%, there is a possibility of cancer in all nodules. Therefore, biopsy should be taken from all nodules and total or near total thyroidectomy should be preferred in these cases [1]. However, in a study by Kuo et al. [8], if the tumor size is less than 0.5 cm, there is no change in prognosis compared to single-focus tumors .

One of the important problems in FNA is the high rate of cytological findings that can not be determined. In a recent retrospective study by Alshaiikh et al., [9], cytological examination was

performed in FNA made from 681 thyroid nodules. According to the Bethesda classification, 10.1% of the cases were found to be non-diagnostic [9].

In a study conducted by Labourier et al., It was shown that Positive Predictive Values (PPV) can increase up to 97% in 109 cases with indeterminate cytological findings [10].

Duick et al.[11] stated that 74% of indeterminate nodules are benign in the histopathological examination at the end of the operation, and this rate can be reduced to 7.6% when gene expression classification tests are performed.

In a study of 358 thyroidectomy cases, The result revealed that when Genetic Expression Profiling (GEP) is performed in indeterminate nodules, the rate of diagnostic thyroidectomy can be reduced from 19 % to 7.2 % [12].

When a diagnosis of thyroid nodules is performed, if low risk of malignancy, uncertain cytology or insufficient cytological material is obtained 2 times in FNA; tests with molecular markers in the tissue can be diagnostic. However, due to the common opinion of the European Thyroid Association (ETA) and the Association of Clinical Endocrinologists (ACE), it is relatively expensive. So, they recommend using molecular tests in tissue only in cases that have not been diagnosed with FNA. [13].

Expression of Vascular Endothelial Growth Factor (VEGF) increases in tissue in cancer cases. Salajegheh et al. showed that VEGF A and C increased in 136 thyroid cancer cases [14]. In a study by Gong et al. D2-40, CK19, galactin-3, VEGF and Endothelial Growth Factor Receptor (EGFR) expression were investigated and found high in 38 Papillary Thyroid Cancer (PTC) and 12 Papillary Thyroid Hyperplasia (PTH) cases [15].

Volirinsky et al. [16] indicated that VEGF-C was to be significantly higher in PTC . In a study by Luo et al. VEGF –C and D were found to be significantly higher in thyroid cancer cases [17].

Although cases with FNA also rarely occur; tumor formation, metastasis and death can be seen depending on the inoculation of cancer cells along the needle path. Hayashi et al. [18] found that thyroid cancer (0.15%) located along the needle pathway as a result of biopsy from thyroid tumor in 22 of 11.745 patients who had

FNA, metastasis in 10 cases (33.3%), in 8 cases, thyroid tumor (0.37) located along the needle pathway from the lymph node needle biopsy was detected. Disease-related death was observed in 4 of these patients. Cumulative tumor cell inoculation risk was found to be 0.34% in 11.745 patients who had FNA. In a study by Nandedkar et al. in India, 20% of the nodules undergoing biopsy reported that approximately 0.1% of the population had thyroid cancer [19]. Considering that FNA is routinely performed in each thyroid nodule, it can be predicted that; tumor development due to cancer cell inoculation, the risk of metastasis and death may arise in a significant number of patients.

Increased expression of some miRNA types in serum as biomarkers in the diagnosis of TC has emerged as one of the most promising noninvasive inexpensive methods. In a study by Rezai et al., with the serum of patients with PTC, compared miR-222, miR-181a, miR-146a and miR-155-5p expression values in the sera of patients with benign thyroid nodules, found that the difference was significantly higher in papillary thyroid cancer cases [20]. In the study of Zhiyan et al. in 120 PTC, 29 nodular goiter and 131 healthy control groups; miR-346, miR-10a-5p and miR-34a-5p were statistically significantly higher in serum in patients with thyroid cancer [21].

Plasma expressions of 3 types of RNA were monitored dynamically and significant overexpression of miR-222, miR-221 and miR-146b in patients with PTC was determined compared to benign thyroid nodules [22].Therefore it was stated that these 3 microRNAs may be new noninvasive molecular markers in the diagnosis, prognosis and monitoring of PTC.

Fan et al. in a study, they collected serum samples from 57 thyroid cancer and other cancer patients and measured circMAN1A2 in serum samples taken from 121 healthy people as a control group, found that circMAN1A2 upregulation was significantly higher in cancer patients [23]. They stated that circMAN1A2 may be a new and important biomarker in early diagnosis of cancer. In a meta-analysis conducted by Li et al. on the diagnostic value of cir RNA as a biomarker in cancers; 64 single, 13 combined cirRNA analyzes were evaluated, and it was confirmed that combined cirRNA had an important place in cancer diagnosis [24].

In a multi-center study, it has been shown that the sensitivity and specificity rates of these features of nodules in the diagnosis of cancer occur as follows: malignant nodules were a taller than wide shape (sensitivity, 40%; specificity, 91%), a spiculated margin; (sensitivity, 48%; specificity, 92%), marked hypoechogenicity (sensitivity, 41%; specificity, 92%), microcalcification (sensitivity, 44%; specificity, 91%), and macrocalcification (sensitivity, 10%; specificity, 96%) [25].

In a comparative study conducted by Rosario et al., [26] with Gray Scale US (GSUS) and Doppler US (DUS) in 1502 solid thyroid nodules larger than 1 cm; They showed that when DUS was added to GSUS, the sensitivity increased to 89.4%.

In a study by Rezavi et al. 3531 thyroid nodules (927 malignant, 2604 benign); echogenicity, calcifications, edge properties, halo formation, image and color Doppler, elasticity and stress ratios were investigated. The respective sensitivities and specificities were as follows: elasticity score, 82% and 82%; strain ratio, 89% and 82%; hypoechogenicity, 78% and 55%; microcalcifications, 50% and 80%; irregular margins, 66% and 81%; absent halo sign, 56% and 57%; nodule vertical development, 46% and 77%; and intranodular vascularization, 40% and 61% [27]. In a study conducted by Cantizati et al, Doppler and strain ratio measurements were performed before operation in 315 indeterminate nodule cases. US Elastography (USE) with strain ratio showed 90.6 % sensitivity, 93 % specificity, 82.8 % PPV, 96.4 % Negative Predictive Value (NPV), while US score yielded a sensitivity of 52.9 %, specificity of 84.3 %, PPV 55.6 % and NPV 82.9 %. According to the results of their studies, they emphasized that strain ratio findings are important especially in the separation of malignant nodules in indeterminate thyroid nodules [28].

Validation of the classification of Thyroid Imaging Reporting And Data System (TIRADS) made in 502 nodules was compared with histopathological examination of the surgically resected nodules. Malignancy was 0% (0/116) in TIRADS 2, 1.79% (1/56) in TIRADS 3, 76.13% (185/243) in TIRADS 4 (subgroups: TIRADS 4A 5.88% (1/17), TIRADS 4B 62.82 % (49/78), TIRADS 4C 91.22% (135/148)], and 98.85% (86/87) in TIRADS 5. In cases where FNA was performed, in TIRADS 4 and 5; sensitivity 99.6% (95% CI: 98.9--100.0), specificity 74.35% (95%

CI: 68.7–80.0), PPV 82.1% (95% CI: 78.0–86.3), NPV 99.4% (95% CI: 98.3–100.0), Positive Likelihood Ratio (PLR) 3.9 (95% CI: 3.6–4.2) and a negative likelihood ratio (NLR) 0.005 (95% CI: 0.003–0.04) for malignancy. According to the results of their study, they said that the TIRADS classification is a good method in the selection of cases requiring biopsy [29].

In a study conducted by Liu et al. In 331 nodules, they performed Two-Dimensional Shear Wave Elastography (2D-SWE) after routine US examination in order to separate malignant and benign nodules. According to the findings they obtained in their work, 2D-SWE, although nodules smaller than 1 cm are not very satisfying, they reported that they are effective in differentiating malignant cases in larger nodules [30].

Chug et al. Evaluated the results obtained in their US examination in 167 thyroid nodules according to American Thyroid Association (ATA), British Thyroid Association (BTA) and TIRADS categories. The sensitivity in ATA, in BTA and in TIRADS were found to be 98%, 95%, 94%, respectively [31].

Li and colleagues conducted a study taking into account the sensitivity and costs of molecular tests, and showed that performing molecular tests in patients with uncertain cytology at FNA is less costly than performing FNA every year [32]. Furthermore, Gomez and colleagues reported in a study that total thyroidectomy is more cost-effective than hemithyroidectomy in follicular thyroid cancer [33]. It was reported that only 2 of the 71 cases who had reoperation due to recurrent papillary thyroid cancer had true recurrence, and 69 patients had persistent disease [34].

Considering that the probability of multicentric thyroid cancer is approximately 20% in cases of nodular goiters, performing a total or near total operation in all thyroid nodules at risk of malignancy will decrease the possibility of leaving tumor focus behind by eliminating the possibility of reoperation and also eliminating the possibility of reoperation will reduce costs [8,34,35].

Molecular diagnostic methods have been placed in the algorithm created by Li et al., for the diagnosis of thyroid nodules because it is cost-effective. However, in this algorithm, lobectomy has been suggested for suspected malignancy at

many stages [32] but, since there is a high risk of leaving tumor tissue behind in these cases, reoperation will be required and it will be risky and not cost-effective [33-35]. Thus, development of a new risk free and cost-effective algorithm is required.

The algorithms previously developed for the diagnosis of thyroid nodules reported in the literature were inadequate and a new improved

algorithm is needed. Therefore, new algorithm is the aim of this investigation to figure out more sensitive, risk free, cost-effective, besides diagnosis, which help to select the type of surgeries to be performed.

2. METHODS

The new algorithm created is listed in Fig. 1.

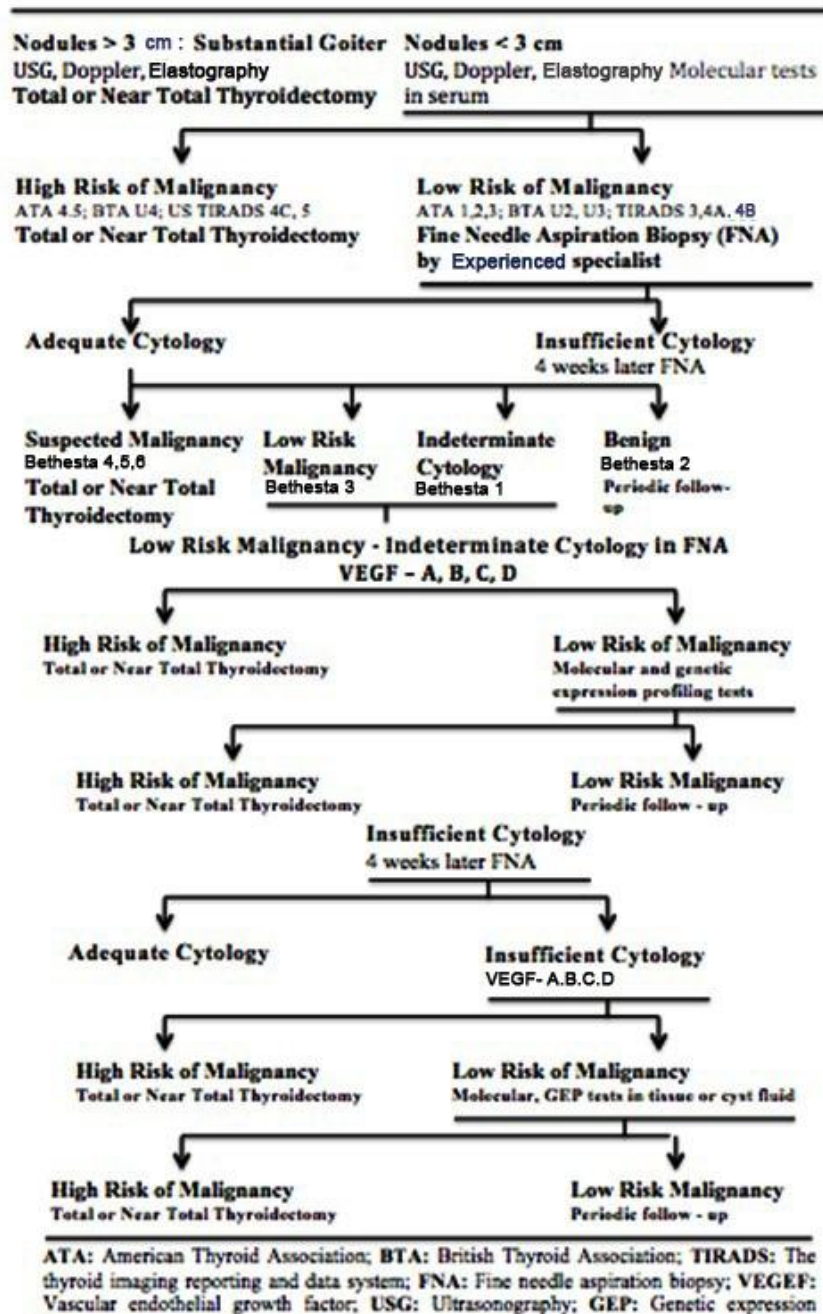


Fig. 1. A new algorithm in the diagnosis of thyroid nodules

2.1 In Nodules Larger than 3 cm and in Cases of Substernal Goiter

The rate of false negative findings increases in nodules larger than 3 cm [2,3]. Also, as the size of the nodules increases, the symptoms of compression on the trachea increase. In the study conducted by Eng et al., he reported that the nodules larger than 1.5 cm had relief in the neck of the patient after thyroidectomy [36]. For these reasons, in patients with thyroid nodules larger than 3 cm and substernal goiter, thyroidectomy should be performed immediately after non invasive diagnostic methods are applied without FNA (Fig. I).

2.2 In Cases of Nodular Goiter Smaller than 3 cm

When multiple non invasive diagnostic methods are applied in thyroid nodules, sensitivity rates increase [20-31]. In addition, in a study conducted by us; it has been demonstrated that the absolute sensitivity rates of noninvasive serum molecular marker tests in the diagnosis of thyroid cancers are higher than those of invasive biopsy methods[37].

Therefore, in cases with high risk of malignancy in multiple non invasive diagnostic tests, eliminating the risk of tumor inoculation (0.34%), total or near total thyroidectomy should be performed without FNA [8,18,19,34,35] (Fig. I).

2.3 In Cases of Nodular Goiter with Low Risk in Noninvasive Diagnostic Tests

FNA should be performed by an experienced specialist [4-9,19]. When FNA is performed by experienced specialist, insufficient cytological finding rate has been shown to decrease [6] (Fig. I).

2.4 In Cases of Nodular Goiter with High Risk of Malignancy in FNA

In cases with high suspicion of malignancy in FNA, total or near total thyroidectomy should be performed [8,34,35]. Because in most of these cases, the histopathological result will be malignant [4-9,19] (Fig. I).

2.5 In Cases with benign Cytological Findings in FNA

Periodic follow-up is sufficient every year in cases with benign outcome in FNA.

The probability of malignancy is very low in these cases with non invasive multiple diagnostic methods and FNA performed [4-9,19-31] (Fig. I).

2.6 In Cases with Low Risk Malignancy and Uncertain Cytological Results in FNA

When molecular tests, genetic expression tests and VEGF expression studies were performed in cases with uncertain cytology and in cases with low risk malignancy in FNA, the rates of diagnosis were increased. In these cases, since the cost of molecular tests and gene tests is high, VEGF tests should be performed first [14-17]. Total or near total thyroidectomy should be performed in cases with high risk of malignancy [8,34,35]. Molecular and gene tests in tissue should be performed in patients with low risk of malignancy in VEGF tests [10-13]. As a result of these tests, total or near total thyroidectomy should be performed in patients with high risk of malignancy. Periodic follow-up should be performed in cases with low risk of malignancy. After applying the multiple non invasive and invasive diagnostic methods mentioned above in these cases, the risk of malignancy will be extremely low [10-17] (Fig. I).

2.7 In Cases with Insufficient cytological Results in FNA

After a 4-week period, FNA is performed again by experienced specialist under the guidance of US. If the result is undiagnostic or insufficient cytology, VEGF tests should be performed first. Total or near total thyroidectomy should be performed in cases with high risk of malignancy [8,34,35]. Molecular and gene tests should be performed in patients with low risk of malignancy in VEGF tests. As a result of these tests, total or near total thyroidectomy should be performed in patients with high risk of malignancy. Periodic follow-up should be performed in cases with low risk of malignancy. After applying the multiple non invasive and invasive diagnostic methods mentioned above in these cases, the risk of malignancy will be extremely low [10-17] (Fig. I).

In our study, for the first time in the algorithms created for the diagnosis of thyroid nodules, based on the results obtained in current studies on this subject, priority is given to non-invasive serum molecular markers over invasive biopsy methods.

The difference and advantage of this algorithm over others; in order for the algorithm to be more sensitive, risk free and cost-effective, the most appropriate diagnostic methods are recommended at each stage, as well as which operations should be performed at which stage. However, in order to reach a definitive conclusion in this regard, this model should be applied in large case series and the results should be carefully evaluated.

The weakness of our work; there is no study in the literature where the above algorithm is applied. We have just started such a study. Therefore, we are currently unable to quantitatively report the advantages of this algorithm.

3. CONCLUSIONS

- Thyroidectomy should be performed after some noninvasive tests in nodular goiter larger than 3 cm and in substernal goiter.
- Primarily non invasive multiple diagnostic methods should be used in the diagnosis of thyroid nodules less than 3 cm.
- FNA is still present an effective, relatively inexpensive and low-risk method in the diagnosis of thyroid nodules. However, it should not be done in every case of thyroid nodules.
- Irrespective of the size of the nodule and the kind of the diagnostic test; when a high risk of malignancy is seen, total or near total thyroidectomy should be performed.

DATA AVAILABILITY

The data used to support the findings of this study are available from the corresponding author upon request.

CONSENT

It's not applicable.

ETHICAL APPROVAL

It's not applicable.

COMPETING INTERESTS

Authors have declared that no competing interests exist.

REFERENCES

1. Acar H (ed.). *Tiroid ve Paratiroid Cerrahisi*. Ankara. 1st edn. Art yayincilik. 2011;104–105.

2. Pinchot SN, Al-Wagih H, Schaefer S, Sippel R, Chen H: Aspiration biopsy for predicting neoplasm or carcinoma in thyroid nodules 4 cm or larger. *Arch Surg*. 2009;144(7):649-655. DOI: 10.1001/archsurg.2009.116
3. Giles WH, Maclellan RA, Gawande AA, Ruan DT, Alexander EK, Moore FD, et al. False negative cytology in large thyroid nodules. *Ann surg Oncol*. 2015;22:152-157. DOI: 10.1245/s10434-014-3952-7
4. Raad RA, Prasad M, Baldassari R, Schofield K, Callender GG, Chhieng D, et al. The value of negative diagnosis in thyroid fine-needle aspiration: A retrospective study with histologic follow-up. *Endocr Pathol*. 2018;29:269-275. DOI: 10.1007/s12022-018-9536-5.
5. Yoon JH, Hee YK, Min JM, Kim J, Kim EK: The diagnostic accuracy of ultrasound-guided fine-needle aspiration biopsy and the sonographic differences between benign and malign thyroid nodules 3 cm or larger. *Thyroid*. 2011;21(9):993-1000. DOI: 10.1089/thy.2010.0458.
6. Choi SH, Han KH, Yoon JH, Moon HJ, Son EJ, Youk JH, et al. Factors affecting inadequate sampling of ultrasound-guided fine-needle aspiration biopsy of thyroid nodules. *Clin Endocrinol*. 2011;74(6):776-782. DOI: 10.1111/j.1365-2265.2011.04011.x.
7. Ospina NS, Brito JP, Maraka S, De Ycaza AEE, Gutierrez RR, et al. Diagnostic accuracy of ultrasound-guided fine needle aspiration biopsy for thyroid malignancy: Systematic review and meta-analysis. *Endocrine*. 2016;53:651-661. DOI: 10.1007/s12020-016-0921-x.
8. Kuo SF, Chao TC, Chang HY, Chung CH, Yang H, Lin JD: Prognostic evaluation of patients with multicentric papillary thyroid microcarcinoma. *J Formos Med Assoc*. 2011;110(8):511-517. Available:<http://www.jfma-online.com>
9. Alshaiikh S, Harb Z, Aljufairi E, Almahari SA: Classification of thyroid fine-needle aspiration cytology into Bethesda categories: An institutional experience and review of the literature. *Cytojournal*. 2018;15(4). DOI: 10.4103/cytojournal.cytojournal_32_17
10. Laborier E, Shifrin A, Busseniers AE, Lupo MA, Mangenelli ML, Andruss B, et al. ISBN: 978-605-61078-0-1

- Molecular testing for miRNA, mRNA, and DNA on fine-needle aspiration improves the preoperative diagnosis of thyroid nodules with indeterminate cytology. *J Clin Endocrinol Metab.* 2015;100(7):2743-2750. DOI: 10.1210/jc.2015-1158.
11. Duick DS, Kloppner JP, Diggans JC, Friedman L, Kennedy GC, Lanman RB, et al. The impact of benign gene expression classifier test results on the endocrinologist–patient decision to operate on patients with thyroid nodules with indeterminate fine-needle aspiration cytopathology. *Thyroid.* 2012;22(10):996-1001. DOI: 10.1089/thy.2012.0180.
 12. Dedhia PH, Rubio GA, Cohen MS, Miller BS, Gauger PG, Hughes DT: Potential effects of molecular testing of indeterminate thyroid nodule fine needle aspiration biopsy on thyroidectomy. *World J Surg.* 2014;38:634-638. DOI: 10.1007/s00268-013-2430-x.
 13. Gharib H, Papini E, Paschke R, Duick DS, Valcavi R, Hegedüs L and Vitti P: AACE/AME/ETA Task force on thyroid nodules: American Association of Clinical Endocrinologists, Associazione Medici Endocrinologi and European Thyroid Association medical guidelines for clinical practice for the diagnosis and management of thyroid nodules: executive summary of recommendations. *JEndocrinolInvest.* 2010;33:287-291. DOI: 10.3275/7048
 14. Salajegheh A, Pakneshan S, Rahmen A, Dolan-Evans E, Zhang S, Kwong E, et al. Co-regulatory potential of vascular endothelial growth factor-A and vascular endothelial growth factor-C in thyroid carcinoma. *Hum Pathol.* 2013;44(10):2204-12. DOI: 10.1016/j.humpath.2013.04.014.
 15. Gong L, Chen P, Liu X, Han Y, Zhou Y, Zhang W, et al. Expressions of D2-40, CK19, galectin-3, VEGF and EGFR in papillary thyroid carcinoma. *Gland Surg.* 2012;1(1):25-32. DOI: 10.3978/j.issn.2227-684X.2012.03.02
 16. Wolinski K, Stangierski A, Szczpanek-Parulska E, Gurgul E, Budny B, Wrotkowska E, et al. Thyroid marker of malignancy superior to VEGF-A in the differential diagnostics of thyroid lesions. *Plos One.* 2016;11(2). DOI:10.1371/journal.pone.0150124
 17. Luo H, Li J, Yang T, Wang J: Expressions and significance of VEGF-C and VEGF-D in differentiated thyroid carcinoma. *J Clin Otorhinolaryngol Head and Neck Surg.* 2009;23(12):531-534. PMID: 19771906
 18. Hayashi T, Hirokawa M, Higuchi M, Kudo T, Ito Y, Miyauchi A: Needle tract implantation following fine-needle aspiration of thyroid cancer. *World J Surg.* 2020;44:378-384. DOI: 10.1007/s00268-019-05161-1.
 19. Nandedkar SS, Dixit M, Malukani K, Varma AV, Gambhir S: Evaluation of thyroid lesions by fine-needle aspiration cytology according to Bethesda system and its histopathological correlation. *Int J Appl Basic Med Res.* 2018;8(2):76-82. DOI: 10.4103/ijabmr.IJABMR_169_17.
 20. Rezai M, Khamanah AM, Zarghami N, Vosoughi A, Hashemzadeh S: Evaluating pre- and post-operation plasma miRNAs of papillary thyroid carcinoma (PTC) patients in comparison to benign nodules. *BMC Cancer.* 2019;19(690):1-9. DOI: 10.1186/s12885-019-5849-0.
 21. Zhiyan W, Jinru LV, Xuan Z, Zebo H, Zhang H, Liu Q, et al. A three plasma microRNA signature for papillary thyroid carcinoma diagnosis in Chinese patients. *Gene.* 2019; 693:37-45. DOI: 10.1016/j.gene.2019.01.016.
 22. Zhang Y, Xu D, Pan Z, Chen M, Han J, Zhang S, et al. Dynamic monitoring of circulating microRNAs as a predictive biomarker for the diagnosis and recurrence of papillary thyroid carcinoma. *Oncol Lett.* 2017;13(6):4252-4266. DOI: 10.3892/ol.2017.6028.
 23. Fan CM, Wang JP, Tang YY, Zhao J, He SY, Xiong F, Guo C, et al. circMAN1A2 could serve as a novel serum biomarker for malignant tumors. *Cancer Sci.* 2019;110(7):2180-2188. DOI: 10.1111/cas.14034.
 24. Li J, Li H, Xiaoting Lv, Yang Z, Gao M, Bi Y et al. Diagnostic performance of circular RNAs in human cancers: A systematic review and meta-analysis. *Mol Genet Genomic Med.* 2019;7(7): e00749. DOI: 10.1002/mgg3.749
 25. Moon WJ, Baek JH, Jung SL, Kim DW, Kim EK, Kim JY, et al. Ultrasonography and the ultrasound-based management of thyroid nodules: Consensus statement and

- recommendations. Korean J Radiol. 2011;12(1):1-14.
DOI: 10.3348/kjr.2011.12.1.1.
26. Rosario PW, Silva AL, Borges MAR, Calsolari MR: Is Doppler ultrasound of additional value to gray-scale ultrasound in differentiating malignant and benign thyroid nodules? Arch Endocrinol Metab. 2015;59(1):79-83.
DOI: 10.1590/2359-3997000000014.
27. Razavi SA, Hadduck TA, Sadigh G, Dwamena BA: Comparative effectiveness of elastographic and b-mode ultrasound criteria for diagnostic discrimination of thyroid nodules: A meta-analysis. Neuroradiol. /Head and Neck Imaging. 2013;200(6):1317-1326.
DOI: 10.2214/AJR.12.9215.
28. Cantisani V, Maceroni P, Andrea VD, Patrizi G, Segni MD, Vito CD et al. Strain ratio ultrasound elastography increases the accuracy of colour-Doppler ultrasound in the evaluation of Thy-3 nodules. A bi-centre university experience. Eur Radiol. 2016;26: 1441-1149.
DOI: 10.1007/s00330-015-3956-0.
29. Horvath E, Silva CF, Majlis S, Rodriguez I, Skoknic V, Castro A, et al. Prospective validation of the ultrasound based TIRADS (Thyroid Imaging Reporting And Data System) classification: Results in surgically resected thyroid nodules. Eur Radiol. 2016;27:2619-2628.
DOI: 10.1007/s00330-016-4605-y.
30. Liu B, Liang J, Zheng Y, Xie X, Huang G, Zhou L, et al. Two-dimensional shear wave elastography as promising diagnostic tool for predicting malignant thyroid nodules: A prospective single-centre experience. Eur Radiol. 2015;25: 624-634.
DOI: 10.1007/s00330-014-3455-8.
31. Chug CL, Tan HC, Too CW, Lim WY, Chiam PPS, Zhu L, et al. Diagnostic performance of ATA, BTA and TIRADS sonographic patterns in the prediction of malignancy in histologically proven thyroid nodules. Singapore Med J. 2018;59(11):578-583.
DOI: 10.11622/smedj.2018062.
32. Li H, Robinson KA, Anton B, Saldanha IJ, Ladenson PW: Cost –effectiveness of a novel molecular test for cytologically indeterminate thyroid nodules. J Clin Endocrinol Metab. 2011;96(11):1719-1726.
DOI: 10.1210/jc.2011-0459.
33. Gomez CC, Vega S, Dominguez LC, Osorio C: Total thyroidectomy versus hemi thyroidectomy for patients with follicular neoplasm. A cost-utility analysis. Int J Surg. 2014;12(8):837-842.
DOI: 10.1016/j.ijssu.2014.07.005.
34. Bates MF, Lamas MR, Randle RW, Long KL, Pitt SC, Schneider DF, Sippel RS: Back so soon? – Is early recurrence of papillary thyroid cancer really just persistent disease? Surgery. 2018;163(1):118-123.
DOI: 10.1016/j.surg.2017.05.028.
35. Lin JD, Chao TC, Hsueh C, Kuo SF: High recurrent rate of multicentric papillary thyroid carcinoma. Ann Surg Oncol. 2009;16(9):2609-2616.
DOI: 10.1245/s10434-009-0565-7.
36. Eng OS, Potdevin L, Davidov T, Lu SE, Chen C, Trooskin SZ: Does nodule size predict the compressive symptoms in patients with thyroid nodules? Gland Surg. 2014;3(4):232-236.
DOI: 10.3978/j.issn.2227-684X.2014.08.03.
37. Acar H, Özer N: What is the Impact of Serum Molecular Markers on the Diagnosis of Thyroid Cancers? A Comparison of Serum Molecular Markers with Invasive Biopsy Methods. Asian Journal of Research and Reports in Endocrinology. 2021;4(2):32-41.

© 2021 Acar and Özer; This is an Open Access article distributed under the terms of the Creative Commons Attribution License (<http://creativecommons.org/licenses/by/4.0>), which permits unrestricted use, distribution, and reproduction in any medium, provided the original work is properly cited.

Peer-review history:
The peer review history for this paper can be accessed here:
<http://www.sdiarticle4.com/review-history/69940>